

Unilateral epididymitis associated with salmonella bacteremia in a dog

Cristina Pérez,^{a*} Michael D. Whitacre,^a Siddhartha Thakur,^b Shivaramu Keelara,^b Megan Fauls,^b Edward B. Breitschwerdt^a

Departments of Clinical Sciences^a and Population Health and Pathobiology,^b College of Veterinary Medicine, North Carolina State University, Raleigh, NC

Summary

This report describes the clinical features, diagnosis and treatment of a dog with unilateral epididymitis associated with *Salmonella* spp. bacteremia. Fever and an enlarged and painful testicle were the main clinical signs that resulted in referral for diagnostic evaluation. Unilateral septic epididymitis was diagnosed via ultrasonography of the genitourinary tract and aerobic culture of scrotal fluid, urine and blood, which yielded heavy growth of *Salmonella* spp. Pulsed-field gel electrophoresis (PFGE) confirmed the presence of *Salmonella javiana*. Following antibiotic therapy there was total resolution of clinical signs, and no *Salmonella* was isolated from a post-treatment urine culture. The source of infection was unknown, however an environmental exposure was suspected. Although infrequent, infection with *Salmonella* spp. should be included in the differential diagnosis of canine epididymitis. Given the major zoonotic importance of salmonellosis, and to prevent re-infection after treatment, the source of the infection should be investigated and eliminated, if possible.

Keywords: Bacteremia, diagnosis, bacteria, blood culture

Case presentation

A four-year-old, 42 kg, intact-male American bulldog was referred to the North Carolina State University Veterinary Teaching Hospital (NCSU-VTH) for evaluation of fever, lethargy and unilateral testicular enlargement of 24 hours duration. After the primary veterinarian identified fever (102.8°F) and an enlarged and painful right testicle, the dog was referred for further evaluation. The owners lived on a large rural cattle and horse farm, and owned four other American bulldogs, three intact males and one spayed female. The dogs remained mostly indoors, but were occasionally left in the yard which shared a common fence with a horse pasture. The dogs had occasional contact with farm animals and many Canada geese were seen around the farm in September when the dog became ill. According to the owners, the dogs sporadically ingested horse feces. Travel history was limited to visits to the primary veterinarian. Flea or tick preventatives were not used, but vaccination status was current and all dogs received year-round heartworm prevention medication (ivermectin). Diet consisted predominantly of dry commercial dog food (Pedigree Adult Complete Nutrition Small Crunchy Bites); however, table food was offered sporadically. According to the owners, the dog was previously healthy and had never been used for breeding purposes.

On admission to NCSU-VTH, the dog was depressed and quiet, body condition score was estimated at 5/9, mucus membranes were pale pink and the capillary refill time was 1 second. Rectal temperature was 103.5°F and the heart rate was 84 beats/min. Femoral arterial pulses were strong and no heart murmur was auscultated. The right testicle and epididymis were markedly enlarged and painful and the scrotum was warm and hyperemic. The left testicle and epididymis were palpably normal. Doppler systolic blood pressures ranged between 100 to 140 mmHg. Hematological abnormalities included leukocytosis characterized by neutrophilia ($29.92 \times 10^3/\mu\text{l}$; reference intervals, $4.39\text{-}11.61 \times 10^3/\mu\text{l}$) and a left shift (bands $598 \times 10^3/\mu\text{l}$) with mild neutrophil toxicity and a monocytosis ($1.197 \times 10^3/\mu\text{l}$; reference intervals, $0.21\text{-}1.05 \times 10^3/\mu\text{l}$). The dog was mildly thrombocytopenic ($178 \times 10^3/\mu\text{l}$; reference intervals, $190\text{-}468 \times 10^3/\mu\text{l}$), mildly hyperglycemic (7.4 mmol/l; reference intervals, 4-6.4 mmol/l), hypokalemic (3.9 mmol/l; reference intervals, 4-5.3 mmol/l) and ALT activity was mildly increased (83 IU/L; reference range, 12-54 IU/L). Prothrombin and activated partial thromboplastin times were normal,

*Current Address: Department of Clinical Veterinary Sciences Veterinary Faculty, University of Helsinki, Finland.

however, d-dimers were moderately increased (500-1000), potentially reflecting a hypercoagulable state. As bacteremia was suspected, three 10-mL blood samples for bacteriologic culture were collected aseptically at 1-hour intervals from the left jugular vein. Urinalysis findings included a urine specific gravity of 1.056 and pyuria (5-10 WBC/hpf), which prompted a urine culture. Due to the thrombocytopenia, a Snap 4Dx (IDEXX Laboratories, Westbrook, ME) for detection of *Anaplasma* spp., *Borrelia burgdorferi*, *Ehrlichia canis* antibodies and *Dirofilaria immitis* antigen was performed, as well as indirect fluorescent antibody testing using *Babesia canis*, *Ehrlichia canis*, *Rickettsia rickettsii*, *Bartonella henselae*, *Bartonella vinsonii* subsp. *berkhoffii* antigens. All serological results were negative. Also, a rapid slide agglutination test (RSAT) was negative for *Brucella canis* antibodies. Ultrasound examination of the genitourinary tract demonstrated marked right epididymal swelling with decreased regional blood flow on Doppler examination, suggestive of thrombosis involving the vessels to the epididymis. There was a large amount of scrotal edema and anechoic fluid surrounding the right testicle and epididymis (Figure 1). The echogenicity of both testicles appeared normal. The prostate was hyperechoic and measured 38.5 mm, which was consistent with benign prostatic hypertrophy. With the dog under sedation, free scrotal fluid (3 ml) was obtained for analysis and aerobic culture, using a 22-gauge needle connected to a 6 ml syringe, under ultrasound guidance. The dog did not show discomfort during or after the procedure. Cytopathology of the scrotal fluid and fine needle aspiration cytology of the right epididymis were consistent with septic suppurative inflammation, with intra- and extracellular bacilli visualized in both samples. Based on these findings, septic epididymitis with possible thrombosis was diagnosed. After the aforementioned samples were obtained for aerobic and anaerobic bacterial culture, ampicillin-sulbactam (22 mg/kg intravenously q 8 h) and enrofloxacin (5 mg/kg intravenously q 24 h) were administered in conjunction with maintenance fluid therapy, ondansetron (0.2 mg/kg intravenously q 8 h) for nausea and hydromorphone (0.5 mg/kg intravenously q 8 h) for pain control. Within 18 hours of incubation, all three blood cultures, the urine culture and the scrotal fluid culture yielded a heavy growth and pure culture of *Salmonella* spp. Based on the sensitivity results, the organism was susceptible to cephalosporins, aminopenicillins, and resistant to aminoglycosides. Pulsed-field gel electrophoresis confirmed the presence of *Salmonella javiana*.

The dog was immediately transferred to the isolation ward, where special handling and personal protective measures were instituted according to NCSU-VTH Infection Control Policies. Because hydromorphone alone failed to control testicular pain, fentanyl was administered at a constant rate of infusion (CRI) at 2 µg/kg intravenously. The dog developed stranguria, but continued to completely empty the urinary bladder after diazepam (0.3 mg/kg intravenously q 12 h) and phenoxybenzamine (0.25 mg/kg orally q 12 h) were prescribed for possible urethral sphincter dyssynergia. A complete blood count 48 hours after admission identified persistent leukocytosis characterized by neutrophilia ($30.76 \times 10^3/\mu\text{l}$), with resolution of the left shift and neutrophil toxicity and increased monocytosis ($3.076 \times 10^3/\mu\text{l}$). Thrombocytopenia persisted ($172 \times 10^3/\mu\text{l}$; reference intervals, $190\text{-}468 \times 10^3/\mu\text{l}$) and D-dimers remained unchanged. By the next day, the dog's attitude and appetite had improved and the testicular region was less painful, but remained very swollen. A fentanyl patch (100 µg/h) was placed and tramadol (5 mg/kg orally q 8-12h) was prescribed. The fentanyl CRI was gradually decreased and the dog was discharged from isolation to the owners with instructions to administer the following medications: enrofloxacin 5mg/kg orally q 24 h for six weeks, tramadol 5 mg/kg orally q 8 h until recheck, carprofen 2 mg/kg orally q 12 h for five days, and phenoxybenzamine 0.25 mg/kg orally q 12 h until urination was normal. Specific precautions including limiting exposure to other dogs and avoiding contact with urine and feces to prevent zoonotic infection were provided to the owners. A sample of the dog's food (approximately 100 g) cultured negative for *Salmonella* spp. Additionally, the owners were asked to bring a small, fresh sample of feces from each of the other dogs in the household (properly identified) for culture and PFGE analysis. Samples from three dogs were negative by culture for *Salmonella* spp., whereas the fecal culture from one dog was positive, so antibiotic therapy was instituted for that housemate. Pulsed-field gel electrophoresis was used to determine the clonal relationship among the *Salmonella* isolates from this dog and the housemate using the PulseNet protocol.¹ Clonal relationships among the isolates were analyzed using Bionumerics version 6.1 (Applied Maths, Austin, TX) by

UPGMA method with tolerance and optimization of 1.5% each. The genotyping profiles of the *Salmonella* isolates from the patient (blood, urine, scrotal fluid) and the fecal isolate from the housemate matched 100%, which suggested infection with the same strain of *Salmonella* in both dogs (Figure 2).

On subsequent examination ten days following diagnosis, the dog was urinating normally and his right testicle and epididymis had decreased in size. A complete blood count documented resolution of the thrombocytopenia ($398 \times 10^3/\mu\text{l}$) and diminished leukocytosis ($12.72 \times 10^3/\mu\text{l}$). The RSAT was again negative for *B. canis* antibodies. Despite the recommendation for bilateral castration, the owners elected unilateral castration so as to maintain the dog for breeding purposes. Unilateral orchiectomy was performed two weeks later while the dog continued receiving antibiotics. Pre-operatively, urine and blood cultures were negative. Histopathology of the testicle and epididymis was consistent with chronic moderate neutrophilic and lymphohistiocytic epididymitis with secondary diffuse, marked hypospermatogenesis. Aerobic culture of the testicle was negative. On reevaluation at NCSU-VTH four months later, the findings of the physical examination were unremarkable. Following manual ejaculation, 5.5 ml of bloodstained semen was obtained. Total spermatozoa count was 347.16×10^6 . Total motility was 80% with 70% progressively motile sperm, resulting in 263×10^6 total motile spermatozoa. Morphologically 79% of the sperm were anatomically normal, with 15% primary abnormalities and 6% secondary abnormalities. Given the presence of blood in the ejaculate and one remaining testicle the dog was considered questionable as a potential breeding animal. The owners declined repeat blood culture, aerobic culture of sperm or urine, prostatic evaluation, and surgical removal of the remaining testicle. Six months later, the owners called the NCSU-VTH to report that the dog had successfully bred a bitch that subsequently delivered 12 puppies.

Discussion

This report describes the clinical and pathological features of a dog with unilateral epididymitis associated with *Salmonella* spp. bacteremia. The authors were unable to find other case reports describing *Salmonella* bacteremia with concurrent genito-urinary involvement in dogs. Epididymitis is an inflammatory reaction of the epididymis, which can be associated with an infectious or non-infectious etiology.^{2,3} The epididymes may become infected by direct penetrating wounds, by hematogenous or lymphatic spread from distant sites, or via the ductus deferens. The diagnosis is based on the clinical signs, which most often include a painful, swollen scrotum, and fever. Ultrasonography of the testes in this dog identified unilateral swelling of the tail of the epididymis and spermatic cord, with diffuse or focal hypoechoic areas which helped exclude neoplasia and testicular torsion as differential diagnoses.³ The right epididymis was markedly enlarged and the diameter in the transverse plane was almost equal to the diameter of the testicle. The diameter of a normal canine epididymis should not be more than 28% of the testis at its greatest width.⁴

Salmonella sp. are gram-negative facultative intracellular anaerobes that cause a wide spectrum of disease.⁵ Although classically considered intestinal bacteria, salmonellosis may manifest clinically as acute enterocolitis, extra-intestinal localized disease, bacteremia, or endotoxemia. Localized infections involving specific tissue sites may occur in association with clinical or subclinical bacteremia.⁶ Epididymitis associated with *Salmonella* species has been rarely reported in domestic animals. In humans, involvement of the genito-urinary tract is also rare, but can occur as a complication of enteric salmonellosis, or in association with congenital urogenital abnormalities, malignancy or immune suppression.⁶⁻⁸ In a review of more than 700 cases of human extra-intestinal infections caused by *Salmonella* spp., Cohen et al found only 12 cases (1.4%) of orchitis and epididymitis.⁶ In dogs, clinical salmonellosis is rare compared to the prevalence of subclinical intestinal infection, as *Salmonella* spp. have been isolated from the feces of up to 36% of healthy dogs.⁵ Ingestion of contaminated food, water or fomites are the most common sources of *Salmonella*.⁵ Raw and improperly cooked cat or dog food products prepared from contaminated meat and meat by-products have a higher prevalence of bacterial contamination than heat-processed foods. However, even commercially processed foods can become contaminated with *Salmonella* spp. if exposed to feces from infected animals or fomites.^{3,9} In our case, the source of infection was unknown, however, the dog most likely acquired the infection through

environmental exposure to cattle, horses and geese, known to be *Salmonella* sp carriers.^{9,10} Geese in particular can be reservoirs of multidrug resistant *S. enterica* Typhimurium strains.⁹ Whether our patient acquired the infection from his housemate, or both dogs became infected from the same environmental source remains unknown.

The most important agents of canine infectious epididymitis/orcho-epididymitis include *Brucella canis* and *Pseudomonas malei*; however, other bacteria such as *Staphylococcus*, *Streptococcus*, *E. coli*, *Mycoplasma*, *Ureaplasma* and *Chlamydia* have also been reported.¹ Orchitis was diagnosed after experimental infection of *Trypanosoma brucei* in one dog,¹¹ and in association with *Rickettsia rickettsii* infection in two dogs.¹² Investigation of *B. canis* should always be pursued, since it can be transmitted sexually to other dogs and is a zoonotic pathogen. In our case, RSAT for *B. canis* was negative twice, and *Salmonella* was the only organism isolated from blood, scrotal fluid and urine. Antibiotics and anti-inflammatory drugs are generally recommended for the treatment of epididymitis. Castration is usually advised, as the effects of the inflammation may likely have a permanent detrimental effect on spermatogenesis.³ In our case, four months after the diagnosis, the dog was healthy and subsequently successfully sired a litter. In conclusion, although infrequent, infection with *Salmonella* spp. should be included in the differential diagnosis of canine epididymitis. Considering the major zoonotic importance of salmonellosis, and to prevent re-infection following antibiotic treatment, the source of the infection should be investigated and eliminated, if possible.

Learning points

- *Salmonella* spp is a gram negative organism that can cause a variety of extra-gastrointestinal signs in dogs, including epididymitis.
- Ultrasonography of the genitourinary tract is helpful in order to exclude other diagnostic differentials for testicular enlargement, such as testicular torsion or neoplasia.
- Dogs can suffer from salmonella bacteremia without any history of gastrointestinal signs or ingestion of raw meat.

References

1. Ribot EM, Fair MA, Gautom R, et al: Standardization of pulsed-field gel electrophoresis protocols for the subtyping of *Escherichia coli* O157:H7, *Salmonella*, and *Shigella* for PulseNet. *Foodborne Pathog Dis* 2006;3:59-67.
2. Flanders JA, Chlafer DH, Yeager AE: Diseases of the canine testes. In: Bonagura JD, editor. *Kirk's current veterinary therapy XIII*. Philadelphia: W.B. Saunders; 2000. p. 941.
3. Johnston SD, Root K, Olson PNS: Disorders of the canine testes and epididymes. *Canine and feline theriogenology*. Philadelphia, PA: W.B. Saunders Co; 2001.
4. England GCW: Relationship between ultrasonographic appearance, testicular size, spermatozoa output and testicular lesions in the dog. *J Sm Anim Pract* 1991;32:306-311.
5. Greene CE: Salmonellosis. In: Greene CE, editor. *Infectious diseases of the dog and cat*, 3rd edition. Philadelphia: W.B. Saunders; 2006. p. 355-360.
6. Cohen JI, Bartlett JA, Corey GR: Extra-intestinal manifestations of salmonella infections. *Medicine (Baltimore)* 1987;66:349-388.
7. Hakim A, Bradley H: *Salmonella* epididymo-orchitis in infancy and childhood. *Clin Pediatr (Phila)* 1992;31:120-122.
8. Al-Obeid K, Al Khalifan NN, Jamal W, et al: Epididymo-orchitis and testicular abscess caused by *Salmonella enteritidis* in immunocompromised patients in Kuwait. *Med Princ Pract* 2006;15:305-308.
9. Yu CY, Chou SJ, Yeh CM, et al: Prevalence and characterization of multidrug-resistant (type ACSSuT) *Salmonella enterica* serovar Typhimurium strains in isolates from four gosling farms and a hatchery farm. *J Clin Microbiol* 2008;46:522-526.
10. Aceto H, Miller SA, Smith G: Onset of diarrhea and pyrexia and time to detection of *Salmonella enterica* subsp *enterica* in feces in experimental studies of cattle, horses, goats, and sheep after infection per os. *J Am Vet Med Assoc* 2011;238:1333-1339.
11. Morrison WI, Murray M, Sayer PD, et al.: The pathogenesis of experimentally induced *Trypanosoma brucei* infection in the dog. I. Tissue and organ damage. *Am J Pathol* 1981;102:168-181.
12. Ober CP, Spaulding K, Breitschwerdt EB, et al: Orchitis in two dogs with Rocky Mountain spotted fever. *Vet Radiol Ultrasound* 2004;45:458-465.

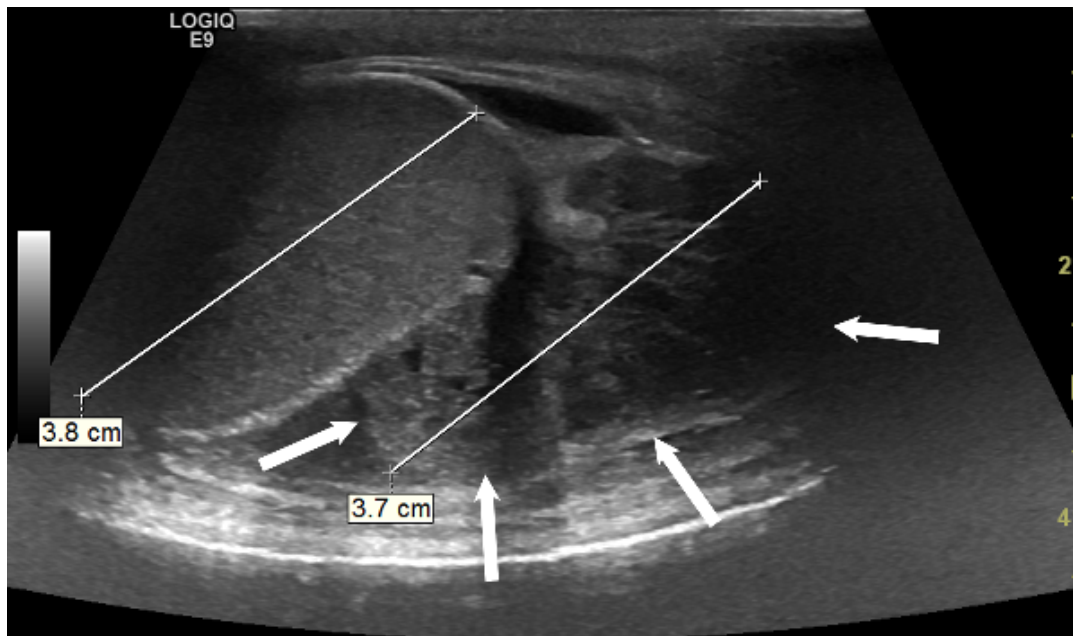


Figure 1: Ultrasound image of the right testicle and epididymis. The epididymal diameter in the transverse plane is almost equal to the diameter of the testicle.

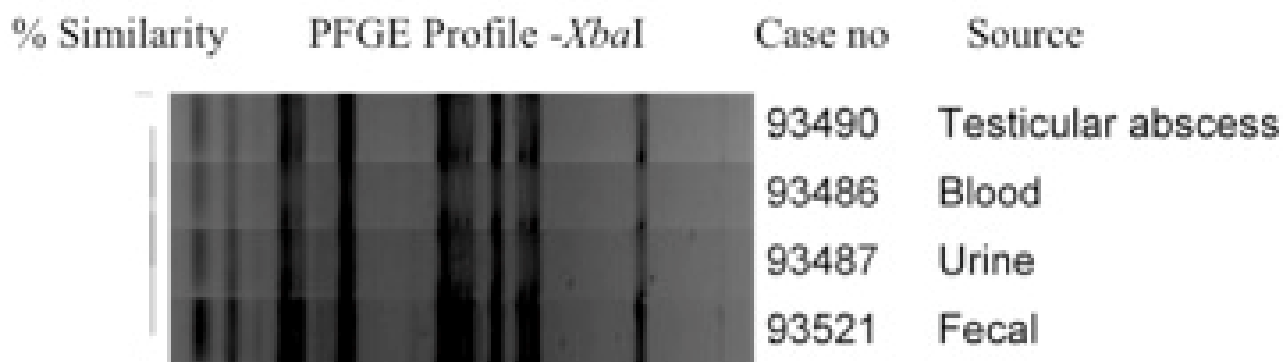


Figure 2. Dendrogram showing the PFGE profiles of the dog *Salmonella* isolates obtained in this study using *Xba*I enzyme.

